

**PATIENT**

Rex Gill

**PRESENTING CLINICAL SIGNS**

History: History of labored breathing while lying down. No coughing and no vomiting or diarrhea. Started on Prednisone 5mg 1/2 EOD with no resolution. No heart murmur. Lung sounds are clear. Sedated with butorphanol.

**SPECIES**

Feline

**ECHOCARDIOGRAM FINDINGS**

2D, m-mode, color flow and doppler imaging is available. The left ventricular wall is normal in dimension. There is a diffusely hyperechoic endocardium consistent with mild fibrosis. The papillary muscles are normal in size and hyperechoic. The endocardium appears normal. The left atrium is normal in size. The right atrium is normal in size. The right ventricle appears normal. The mitral valve is normal in structure and mobility. Normal flow through both the RVOT and LVOT. No obvious TR, AI or PI. No pleural or pericardial effusion seen. No obvious cardiac tumors.

**BREED**

DMH

**CARDIAC CHART****SEX**

Male Neutered

**AGE**

18 months

**WEIGHT**

11.4lbs

**INTERPRETED BY**

Maggie Machen Lamy,  
DVM, DACVIM  
(Cardiology)

FELINE CARDIAC PARAMETERS	BODY WEIGHT (kg)	HR (BPM)	IVSd (cm) (Moise, Pipers)	LVIDd (cm) (Moise, Pipers)	LVWd (cm) (Moise, Pipers)	FS (%)	EF (%)
NORMAL PARAMETER	-----	150-240	0.35-0.55	<2 (mean 1.5)	3.5-0.55	35-67	80-100
PATIENT	5.2	180	0.38	1.56	0.37	45	80
FELINE CARDIAC PARAMETERS	LA/AO (Boon)	LA/AO HEART BASE (Swe) (Abbott)	LA 2D short axis Base view (cm) (Abbott)		LVOT VEL (m/s)	RVOT VEL (m/s)	E max (m/s)
NORMAL	<1.5	<1.3	<1.2		<1.6	<1.3	<0.9
PATIENT	1.5	1.3	1.3		0.7	0.99	NM

*\*Note: All measurements based upon multi-modal images and methods. An average value is reported.  
Adapted from June Boon, Veterinary Echocardiography, 1998  
Abbott J & MacLean H JVIM 2006;20: 111-119, Moise et al. Am J Vet Res 47:1476, 1986. Pipers et al. Am J Vet Res 40:882, 1979.*

**IMAGING PERFORMED BY**

Kim Liedberg

**INTERPRETATION OF THE FINDINGS & FURTHER RECOMMENDATIONS**

Overtly normal cardiac structure and function. The LV wall thickness is normal and there is no evidence of elevated left atrial pressure. No obvious congenital issues are documented.

No cause for labored breathing is seen in this study and other possibilities should be considered.

**HOSPITAL NAME**

SVS Imaging WI

Given these findings, no medications are indicated. It is important to note that phenotypic HCM can develop at any phase of life in cats (particularly in this predisposed breed), and often does not accompany a heart murmur or PE abnormalities. Periodic screening is ideally recommended in all cats.

**REFERRING VET**

Dr. Abraham

No cardiac contraindication for breeding or general anesthesia at this time.

**INVOICE**

28016

Recommend recheck echocardiogram in 1 year to assess for development of disease, sooner if a murmur/gallop or clinical signs develop in the interim.

**DATE**

4/14/22

IMAGING PERFORMED BY

svsmobileimaging.com 309 - 737 - 3070



Clinical Sonography & Telectology

EDUCATIONAL TELECONSULTATION SERVICES™

1-800-838-4268 info@sonopath.com SonoPath.com

**PATIENT**

Rex Gill

**SPECIES**

Feline

**BREED**

DMH

**SEX**

Male Neutered

**AGE**

18 months

**WEIGHT**

11.4lbs

**INTERPRETED BY**

Maggie Machen Lamy,  
DVM, DACVIM  
(Cardiology)

**IMAGING  
PERFORMED BY**

Kim Liedberg

**HOSPITAL NAME**

SVS Imaging WI

**REFERRING VET**

Dr. Abraham

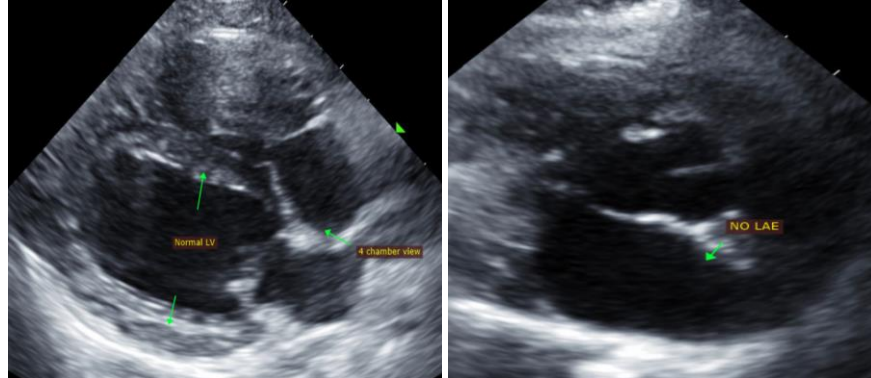
**INVOICE**

28016

**DATE**

4/14/22

**IMAGES**



The information and recommendations provided are based on the images presented by the referring veterinarian. No evaluation can be communicated regarding pathology that was not visible in the image/video clips provided.

Thank you for this referral. If the clinical or image interpretation does not parallel your findings or if I can be of any further assistance, please contact me.

Maggie Machen Lamy, DVM  
Diplomate of the American College of Veterinary Internal Medicine (Cardiology)  
info@sonopath.com